THE USE OF MACHINE LEARNING FOR DATA AUDITING AND PREDICTIVE MODELING OF OPEN THORACOTOMY VERSUS THORACOSCOPIC SURGICAL RESECTIONS FOR CONGENITAL CYSTIC LUNG LESIONS

Presenting Author: Allan F. Simpao, MD[a]

Co-Authors: Radoslav Ivanov,[b] Insup Lee, PhD,[b] Jorge A. Galvez, MD,[a] Mohamed A. Rehman, MD,[a]
[a] Biomedical Informatics Section, Department of Anesthesiology and Critical Care Medicine, The Children's Hospital of Philadelphia, Philadelphia, PA, USA
[b] Department of Computer and Information Science, University of Pennsylvania, Philadelphia, PA, USA

Background: Congenital cystic lung lesions warrant surgical resection to avoid the development of complications later in life (e.g. infection, pneumothorax, hemothorax, malignancy).[1] Thoracoscopic approach generally requires one-lung ventilation to optimize lung visualization.[2] Intraoperative loss of lung isolation is often unanticipated and usually results in conversion to open thoracotomy.

Methods: The AIMS data from patients with congenital lung lesions who underwent elective open and thoracoscopic lung lobectomy surgery between March 2005 and January 2012 were reviewed retrospectively. Existing machine learning algorithms (logistic regression, support vector network (SVN), perceptron) were used to predict the type of lobectomy (open versus thoracoscopic) via vital sign data patterns (Fig 1 and 2). The features chosen included the minimum SpO2 value, the SpO2 value 1, 2, 3, and 4 minutes after the minimum SpO2 value, number of measurements less than 100%, and the mean and variance. The cases that were incorrectly identified by the learning algorithms were analyzed for possible causes.

Results: The data set consisted of 197 open thoracotomies and 95 thoracoscopic elective lobectomy cases. Prediction accuracy of thoracotomy versus thoracoscopic procedures was 80%. The algorithm misidentified more than half of the laparoscopic cases as open cases, mainly due to minimal SpO2 variation. Complications included thoracoscopic cases that were converted to open thoracotomies. During the data analysis, a few cases that were classified by the surgeon as strictly thoracoscopic were identified as open by the machine learning algorithms; these cases were confirmed manually as open cases.

Conclusions: While the use of SpO2 as a feature of the predictive algorithm resulted in a fair accuracy rate, attempts should be made to improve the accuracy using other variables (e.g. ETCO2, respiratory rate, weight, age, tidal volume/weight). Future uses for the predictive algorithm include development of a smart alarm to warn providers of impending loss of lung isolation and one-lung ventilation, as well as the converse (e.g. mainstem intubation in an intubated patient). Future analysis should also lend insight into practices for optimal intraoperative management of one-lung ventilation in infants undergoing lung resection in order to decrease intraoperative SpO2 variation and maximize oxygenation.

References

1. Parikh D, Samuel M. Congenital cystic lung lesions: Is surgical resection essential? Pediatr Pulmonol. 2005 Dec;40(6):533-7.
2. Hammer GB. Single-lung ventilation in infants and children. Paediatr Anaesth. 2004 Jan;14(1):98-102.

Figure 1. Typical thoracoscopic SpO2 (blue) and ETCO2 (red) patterns during cystic adenomatoid malformation resection.

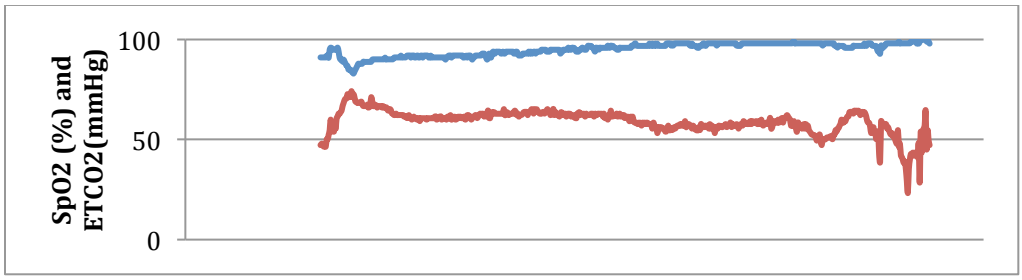

Figure 2. Typical open thoracotomy SpO2 (blue) and ETCO2 (red) patterns during cystic adenomatoid malformation resection.