

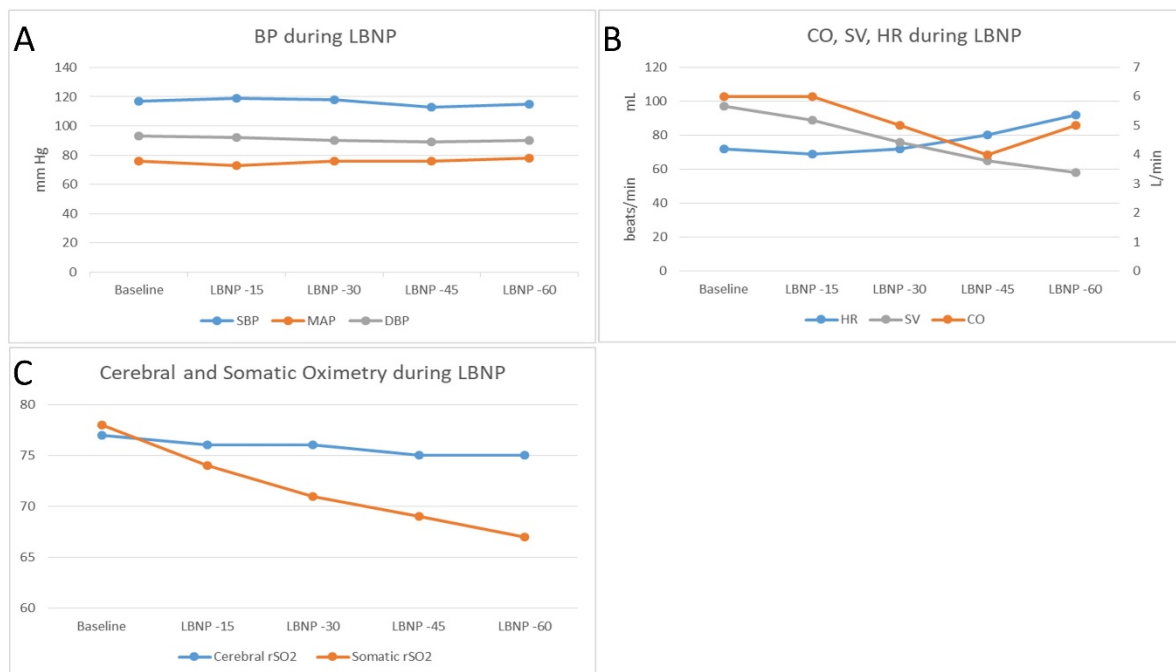
Cerebral vs Somatic Oxygenation as an Early Detector of Hypovolemia

Presenting Author: Aymen Alian, MD - Yale University School of Medicine

Co-Authors: Christopher Choi, MD; Hesham Ezz, MBBCh; Nadeem Elbetbsi, MBBCh; Kirk Shelley, MD, PhD - Yale University School of Medicine

Abstract Content: Technology for measuring tissue oxygen saturation based upon near infrared spectroscopy (NIRS) has become more sophisticated, allowing for reliable measurements of cerebral and regional circulations. Whereas the traditional pulse oximeter monitors peripheral oxygen saturation in pulsatile (arterial) blood, NIRS can identify tissue hypoxia in the absence of macrocirculatory changes (1). We hypothesized that continuous tissue oximetry can detect early changes in local perfusion secondary to hypovolemia that are not reflected by systemic hemodynamic variables alone. 22 healthy volunteers underwent a lower body negative pressure (LBNP) protocol, a well-known method for simulating hypovolemia (2). Cerebral and somatic sensors, five-lead EKG, finger pulse oximetry, blood pressure (BP) and non-invasive cardiac output monitors were applied to all subjects. BP, cardiac output as well as oxygen saturation were maintained during progressive hypovolemia (A). Somatic oxygenation decreased significantly ($P \leq 0.006$) from baseline starting at -15 mmHg and with progressive increases in LBNP, whereas cerebral oxygenation was maintained until -45 mmHg (C). HR showed significant changes only at -45 and -60 mmHg (B). Recognition of hypovolemia can be complicated by compensatory mechanisms such as systemic vasoconstriction and blood flow redistribution. Indeed, in our data, BP and cardiac output were maintained with progressive hypovolemia. Tachycardia, the first clinical sign of significant hypovolemia, was only seen at ~1000 mL blood loss. In contrast, somatic tissue oxygenation was significantly decreased starting at ~333 mL blood loss. Our data shows somatic tissue oxygenation as a promising perfusion-based tool for early recognition of hypovolemia.

Images:



References:

1. Semin Cardiothorac Vasc Anesth 2016;20(3):213-24
2. J Appl Physiol 2004;96:1249-61