

## Remote Observation of Delayed Onset Malignant Hyperthermia: A Case Report

**Presenting Author:** Stuart Solomon, MD (Stanford University)

**Co-authors:** David Trauscht, MD; Rajeev Saxena, MD MBA; Christine Fong, MS; John D Lang, MD; Bala G Nair, PhD MS (University of Washington)

**Case Report:** A 64-year-old man with prior anesthetics and no eventful history was scheduled for resection of a left parotid mass and free flap. Induction was at 07:45 with midazolam, propofol, sufentanil and succinylcholine. The patient was intubated, and anesthesia was maintained with isoflurane, sufentanil infusion and rocuronium. The case proceeded uneventfully with a gradual hypercarbia (ETCO<sub>2</sub> 40-45mmHg) that was corrected with increases in ventilation. At approximately 19:30, or 12 hours after the case began, the ETCO<sub>2</sub> was noted to be 67mmHg, then quickly rose to 88mmHg with worsening acidosis, hyperkalemia to 6.8, concurrent rise in temperature (T<sub>max</sub> 40.5° C), and tachycardia. A diagnosis of MH was established by the anesthesia team in the operating room and appropriately treated with dantrolene and supportive measures. The patient made a successful recovery and was discharged from the hospital on postoperative day eight.

**Remote Surveillance:** We were coincidentally testing a remote vital sign surveillance system via our Operating Room Business Intelligence Software (ORBIS, *University of Washington*) at the time of this case. This system presents operating room data such as case location, start time and case duration in a grid-based dashboard. Vital sign data is processed from a central data storage platform (*Amalga, Microsoft*) obtained from our anesthesia information management system. Icon notifications were created for specific vital sign thresholds such as tachycardia, hypoxemia and hypercarbia. When a patient meets a criterion for a certain vital sign threshold, the notification icon is displayed on the grid corresponding to that case, which can then be clicked on to reveal additional vital sign data and case information (Figure 1). This system is updated in near real-time (approximately every 5 minutes). The aforementioned case of MH displayed the icon notifications for hypercarbia, hyperthermia and tachycardia. The on-call anesthesiologist was contacted due to the observed abnormal vital signs and concern for MH, who communicated that the diagnosis had already been made and was actively being treated at that time.

**Discussion:** Malignant hyperthermia (MH) is a rare hypermetabolic disorder associated with exposure to volatile anesthetics and succinylcholine, and may present with delayed onset to exposure to these agents. Early detection, diagnosis, and treatment with dantrolene is paramount to avoiding a poor outcome. This case represents the potential for remote anesthesia surveillance systems to provide global insight to intraoperative changes and to aid in the recognition and diagnosis of anesthetic emergencies such as MH. Further research is needed to understand how human factors, software design and clinician behavior may impact implementation and effectiveness.

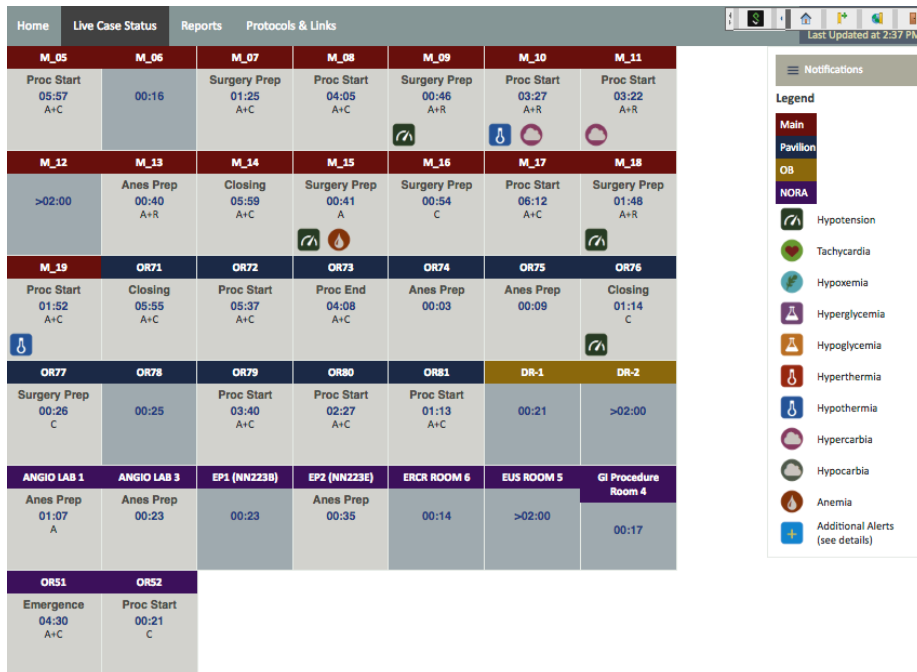


Figure 1: Remote surveillance dashboard depicting operating room times, case status and abnormal vital signs.